

Transpulmonary pressure measurement

Benefit of measuring transpulmonary pressure in mechanically ventilated patients

Dr. Jean-Michel Arnal, Senior Intensivist, Hopital Sainte Musse, Toulon, France

Dr. Dominik Novotni, Manager of Research and New Technology, Hamilton Medical, Bonaduz, Switzerland

Introduction

In mechanical ventilation, basic monitoring combines airway pressure and flow. While the titration of ventilator settings based on measurement of airway pressure may be adequate for most mechanically ventilated patient, we know that this is an oversimplified surrogate for the pressure in the two components of the respiratory system, namely the lungs and the chest wall. It is now widely accepted that chest wall mechanics can be severely abnormal in critically ill patients^{1, 2, 3}. As a continuous effort to improve lung protection, the contribution of chest wall mechanics should not be ignored. Consequently, advanced monitoring in mechanical ventilation adds the measurement of esophageal pressure which is considered as a substitute for pleural pressure. Partitioning of lung and chest wall compliance is then possible and is very useful to assess lung recruitability, perform recruitment maneuvers, set PEEP and tidal volume. Transpulmonary pressure is airway pressure minus esophageal pressure measured during an end-inspiratory or end-expiratory occlusion, and represents the pressure to distend the lung parenchyma. Transpulmonary pressure may allow customization of ventilator settings in order to optimize lung recruitment and protective ventilation in mechanically ventilated patients.⁴

Contraindications

Use of an esophageal catheter is contraindicated in patients with diseases such as esophageal ulcerations, tumors, diverticulitis, bleeding varices, recent esophageal or gastric surgery, sinusitis, epistaxis, or recent nasopharyngeal surgery.

Technique of placement

Preparation

The adult esophageal balloon catheter kit contains an 86 cm closed-end catheter with a 9.5 cm balloon and a stylet together with a pressure extension tube and a 3-way stop-cock. An additional extension line and a 3-5 mL syringe are needed. A topical anesthetic (e.g. lidocaine spray) is required in awake patients (Figure 1).

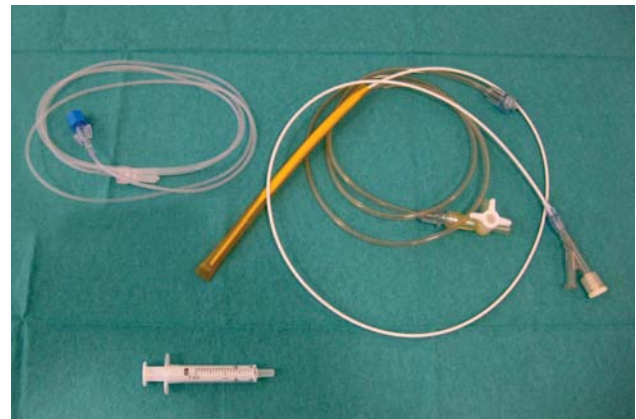

Figure 1: The adult esophageal balloon catheter kit

Connect the extension line to the auxiliary port of the ventilator. Select the display with from top to bottom airway pressure, esophageal pressure, transpulmonary pressure, and flow. Check that esophageal pressure is zero on the waveform (Figure 2).

Placement and measurement of esophageal pressure is easier and more accurate in patients in semi-recumbent position.

Placement

The catheter has depth markings to aid in positioning the balloon in the lower third of the esophagus. The estimated depth in which to place the catheter can be measured by the distance from nostril to ear tragus to xyphoid, or calculated as the patient's height (in cm) x 0.288 (Figure 3).

Step 1

Select a nostril without obstruction and apply a suitable topical anesthetic if the patient is awake. Apply water soluble lubricant to the distal tip of the catheter.

Step 2

With the patient's head in neutral position or flexed slightly forward, slowly insert the catheter through the nostril and hypopharynx using a gentle advancing motion. If the catheter meets obstruction, do not force it. Remove the catheter and insert it through the other nostril. Gently insert the catheter as far as the stomach, which is around 15 cm deeper than the estimated depth (Figure 4).

Step 3

Attach the extension tube to the Y connector of the stylet. Inflate the balloon with 3 ml of air using the 3-way stopcock, then withdraw 2 ml to leave 1 ml of air in the balloon. Turn the stopcock off to the syringe and open to the extension line.

Check the esophageal pressure measurement on the ventilator. Esophageal pressure should increase during inspiration and should increase during a gentle manual compression of the abdominal left upper quadrant. If the esophageal pressure waveform is similar to airway pressure with the same pressures measured during an end-inspiratory occlusion, tracheal placement may be assumed. Deflate the balloon and remove the catheter. Insert the catheter through the other nostril.

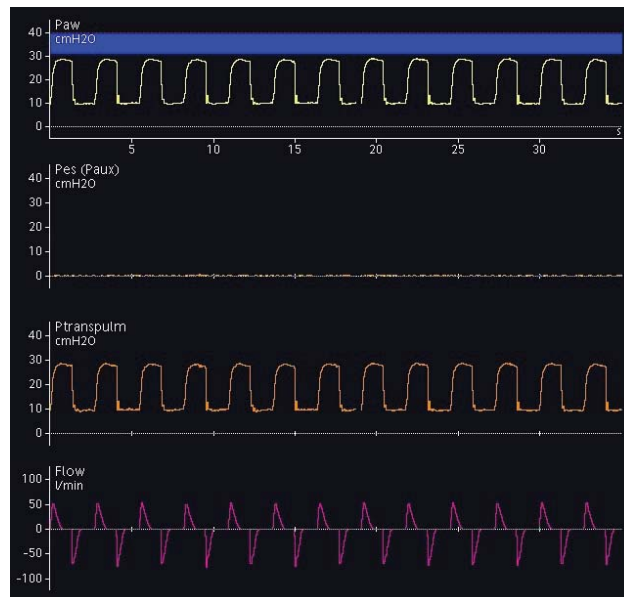


Figure 2: Display of pressures and flow on the ventilator

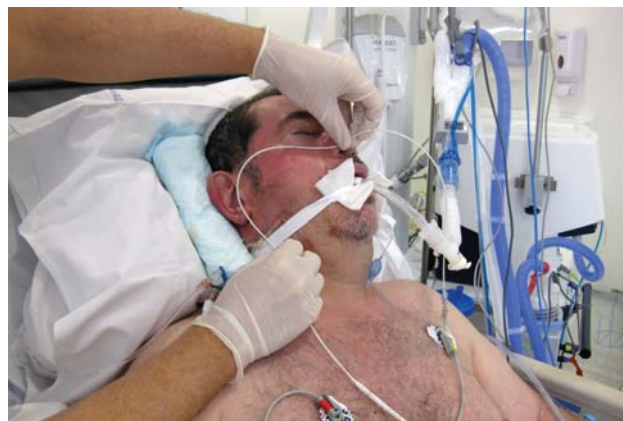

Figure 3: Estimation of the depth to place catheter

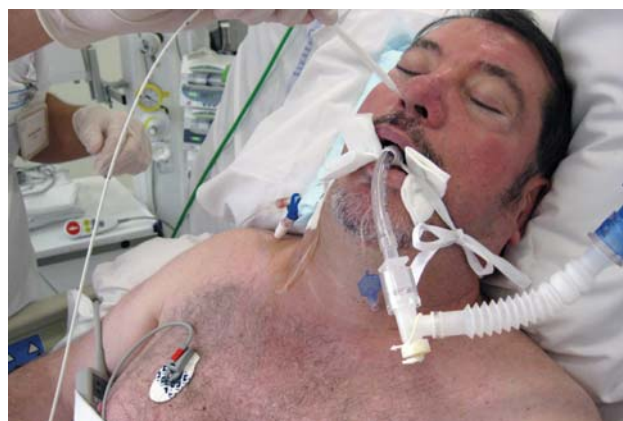

Figure 4: Insertion of the catheter

Step 4

Slowly pull out the catheter to the estimated depth. A qualitative change in the esophageal pressure waveform should be seen with the appearance of cardiac oscillations. In spontaneously breathing patients, esophageal pressure should be negative during inspiration. In passive patients, esophageal pressure is positive during insufflation (Figure 5).

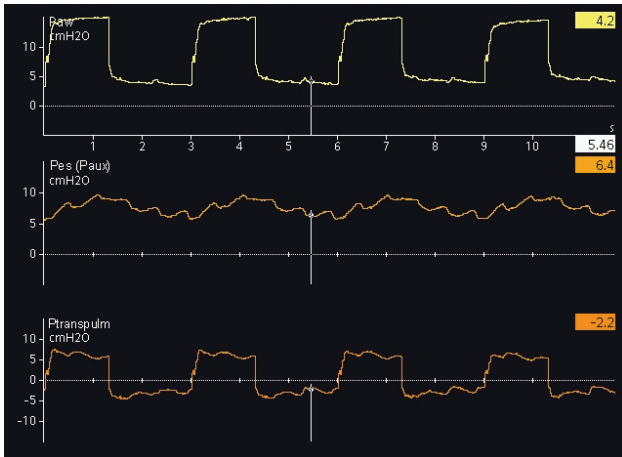


Figure 5: Placement of an esophageal catheter in a passive patient. Esophageal pressure increases during insufflation. The small waveforms are cardiac oscillations

Step 5

When the balloon is in the proper position, disconnect the extension tube and remove the stylet. Connect the extension tube directly to the catheter and inflate the balloon again (see step 3). Secure the catheter with tape to prevent motion removal or displacement (Figures 6 and 7). Never attempt to reinsert the stylet once removed.

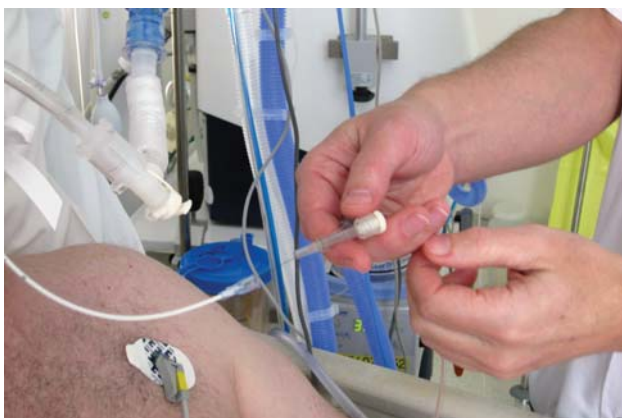

Figure 6: Removal of the stylet and connection to the extension tube

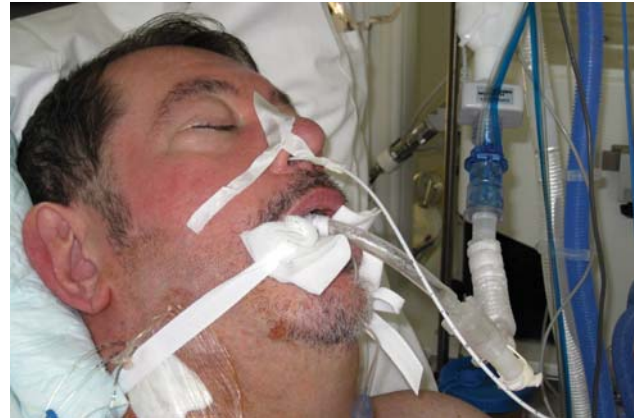

Figure 7: Secure the catheter with tape

If esophageal pressure is measured continuously, repeat step 3 every 30 minutes.

Upon completion of the pressure measurements, deflate the balloon prior to catheter removal.

Trouble shooting

Esophageal pressure is similar to airway pressure

Measure airway and esophageal pressures at end-inspiration and end-expiration using an end-inspiratory and end-expiratory occlusion, respectively. If they are similar, the esophageal catheter has probably been inserted in the trachea. Deflate the balloon and remove the catheter.

Pressure waveform is flat on top

There may not be enough air in the balloon.

Pressure waveform is dampened

There may be too much air in the balloon.

There is no pressure waveform

Check that the connections are adequate. The catheter may need to be advanced further into the esophagus or may be kinked and needs to be withdrawn.

Verification of the correct position

Spontaneously breathing patient: The validity of esophageal pressure measurement can be assessed using the dynamic occlusion test procedure. Patients make three to five inspiratory efforts while airways are occluded at the end of expiration. The correct position of the esophageal balloon is ascertained from the high correlation between swings in airway and esophageal pressure during this maximal effort. The acceptable range of $\Delta P_{es}/\Delta P_{aw}$ during the dynamic occlusion test is from 0.8 to 1.2.^{4, 5} If the patient is not breathing spontaneously (passive condition), the occlusion test is performed by applying manual compression on the chest during airway occlusion.

Correction of measured pressure

Some authors recommend correcting the measured esophageal pressure to take into account the ventral-to-dorsal pleural pressure gradient across the thorax and the weight of the mediastinum, especially in a supine position. The correction can be done by subtracting 5 cmH₂O from the measured value⁶ or by subtracting the esophageal pressure at the end of passive expiration measured after manually disconnecting the patient from the ventilator⁷.

How to interpret esophageal pressure

Airway pressure is the pressure of the whole respiratory system (lung and chest wall). Esophageal pressure is an assessment of pleural pressure, i.e., the pressure to distend the chest wall. An increase in esophageal pressure means that chest wall compliance is decreased, as a result of intra-abdominal hypertension, pleural effusion, massive ascites, thoracic trauma, and edema of thoracic and abdominal tissues as a result of fluid resuscitation.

1. Assessing lung recruitability using a low flow pressure-volume curve

By using esophageal pressure measurement, a low flow pressure-volume (P/V) curve can be partitioned into the chest wall P/V curve and the lung P/V curve. The lung P/V curve is probably more accurate than the respiratory system P/V curve for assessing recruitability. There may be high potential for lung recruitment if the lung P/V curve shows a well-defined lower inflection point and a large hysteresis^{8, 9} (Figures 8, 9-11, 12-14).

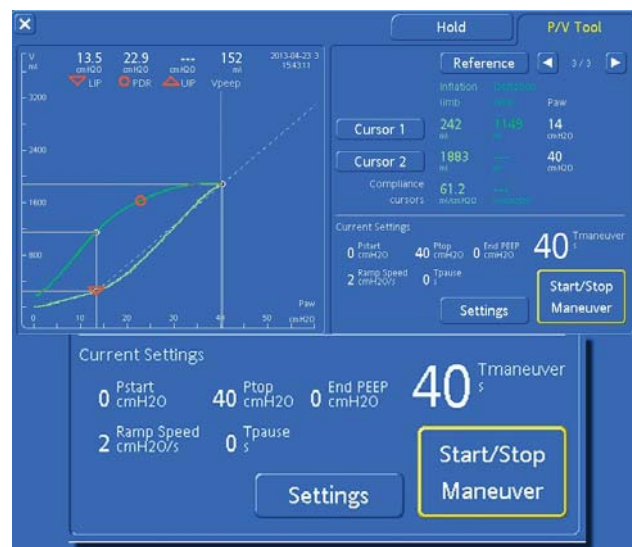

Figure 8: Settings for a pressure-volume curve using the P/V Tool[®] Pro

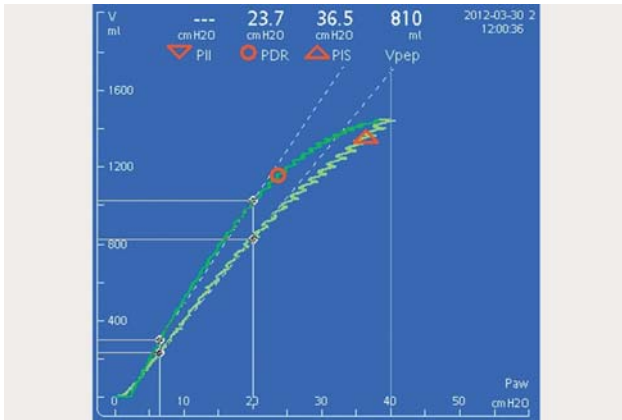


Figure 9: Respiratory system P/V curve using airway pressure in a patient with low potential for recruitment

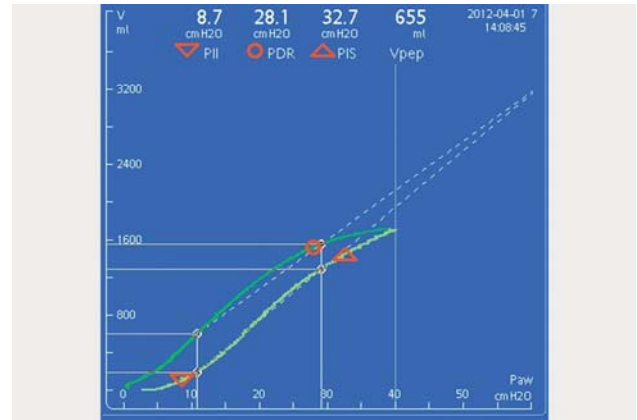


Figure 12: Respiratory system P/V curve using airway pressure in a patient with high potential for recruitment

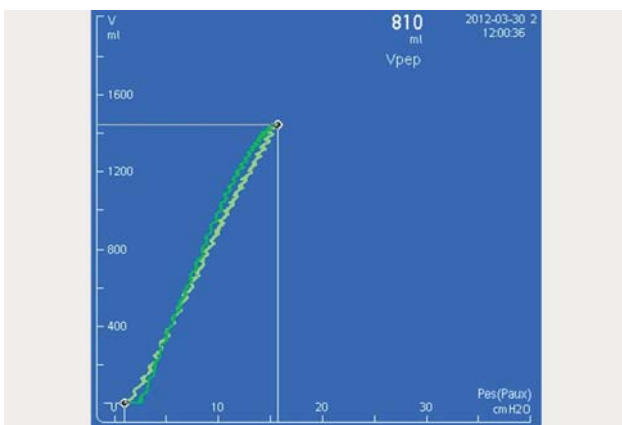


Figure 10: Chest wall P/V curve using esophageal pressure in a patient with low potential for recruitment

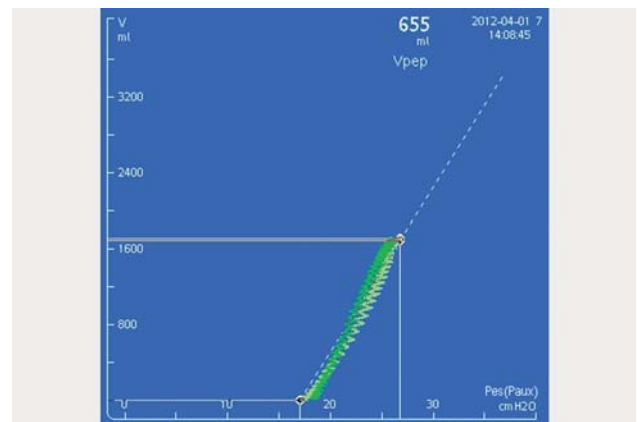


Figure 13: Chest wall P/V curve using esophageal pressure in a patient with high potential for recruitment

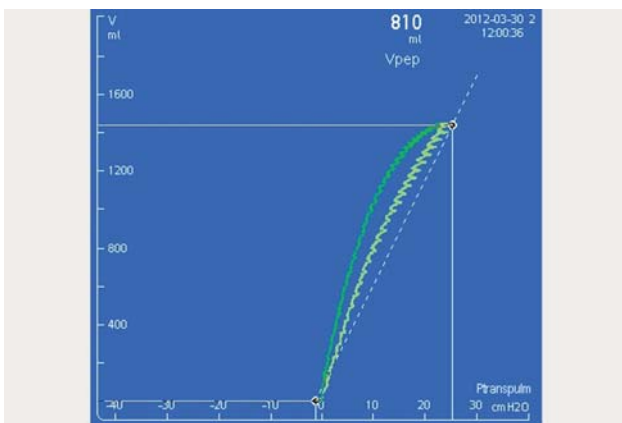


Figure 11: Lung P/V curve using transpulmonary pressure in an early onset ARDS patient. Note the absence of a low inflection point and a narrow hysteresis, meaning that the potential for lung recruitment is probably low. Note also that when airway pressure was increased to 40 cmH2O, transpulmonary pressure was around 25 cmH2O. This means that a recruitment maneuver would potentially harm the lung, while providing no benefit in terms of recruitment

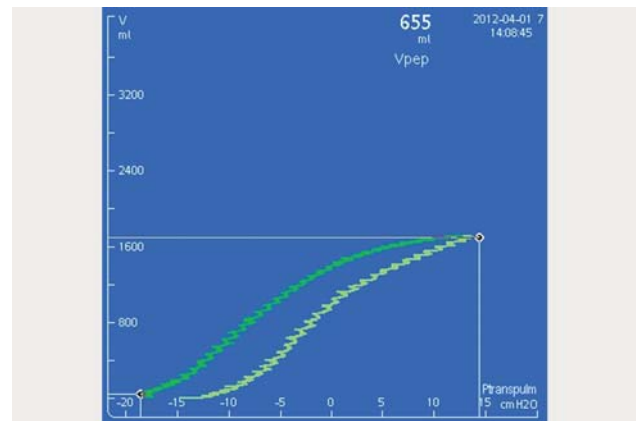


Figure 14: Lung P/V curve using transpulmonary pressure in an early onset ARDS patient. Note the presence of a well-defined lower inflection point and a large hysteresis, meaning that the potential for lung recruitment is probably high. Note also that when airway pressure was increased to 40 cmH2O, transpulmonary pressure was only around 15 cmH2O. This means that if a recruitment maneuver is performed, airway pressure should be set higher than 40 cmH2O

2. Titrating recruitment maneuver

By using esophageal pressure measurement, the pressure to recruit the lung can be titrated. The goal is to reach a transpulmonary pressure of around 25 cmH₂O for the recruitment maneuver to fully recruit the lung and prevent excessive overdistension¹⁰ (Figures 15 and 16-18).

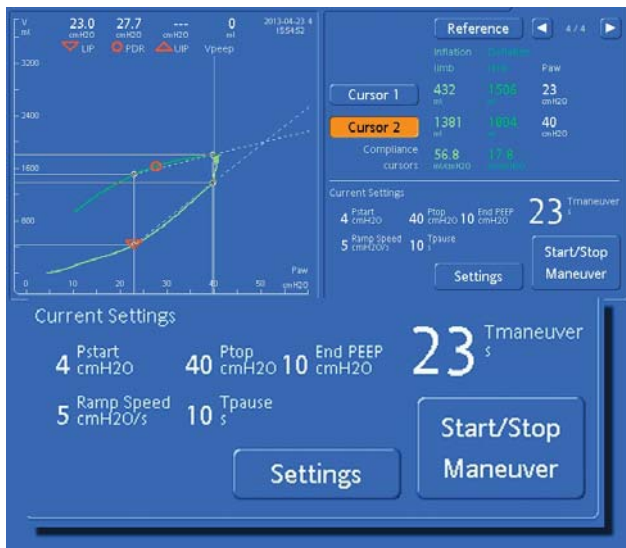

Figure 15: Settings for a recruitment maneuver with the P/V Tool using a fast pressure increase (ramp speed at 5 cmH₂O/s), a pause of 10 s at high pressure, and higher PEEP after the recruitment maneuver

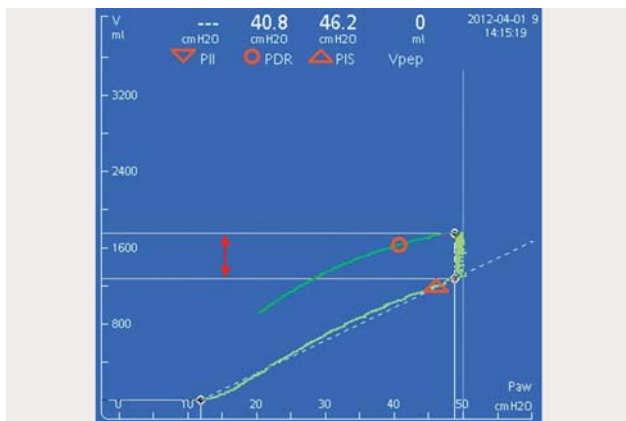


Figure 16: Airway pressure versus volume during a sustained inflation recruitment maneuver

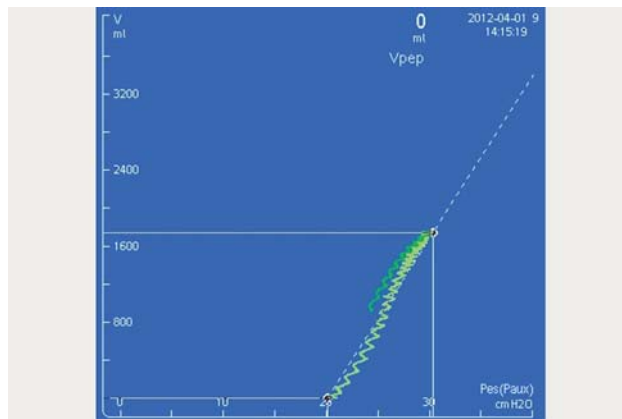


Figure 17: Esophageal pressure versus volume during a sustained inflation recruitment maneuver

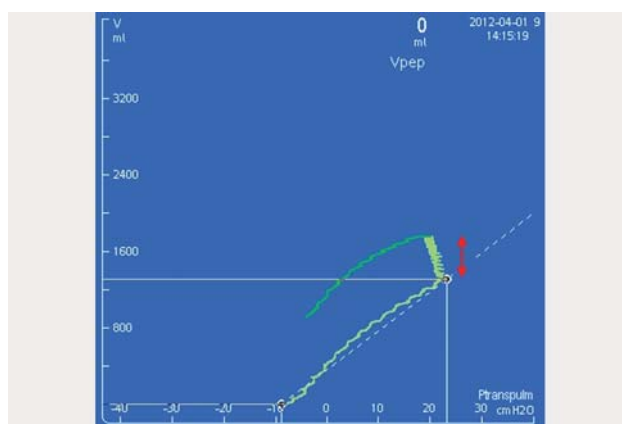


Figure 18: Sustained inflation recruitment maneuver performed with the P/V Tool in an early onset ARDS patient (same patient as in Figures 12-14). Airway pressure (16), esophageal pressure (17) and transpulmonary pressure (18) versus volume during the recruitment maneuver. Note that the top airway pressure was set at 50 cmH₂O in order to have transpulmonary pressure around 25 cmH₂O. The duration of the recruitment maneuver was 10 seconds. Note the increase in volume on the airway and transpulmonary pressure curves (red arrows), which is an assessment of the volume recruited during the recruitment maneuver

3. Setting PEEP

In ARDS patients, PEEP can be set in order to achieve a transpulmonary pressure of 0 to 5 cmH₂O at end-expiration using an end-expiratory occlusion. The rationale is to prevent atelectrauma caused by repeated opening and closing of distal airways and alveoli. In a randomized controlled physiological study, setting PEEP according to transpulmonary pressure was associated with better oxygenation and respiratory system compliance than when using the standard ARDSnet PEEP-FIO₂ table¹¹ (Figure 19).

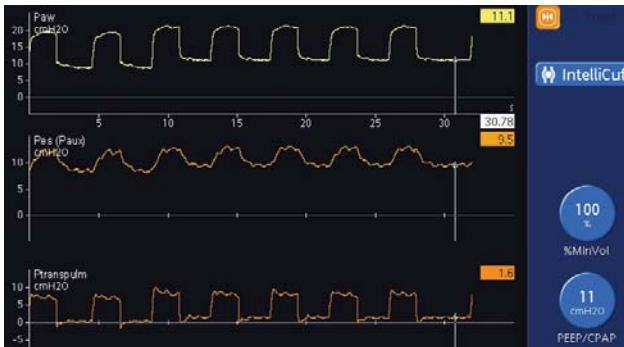
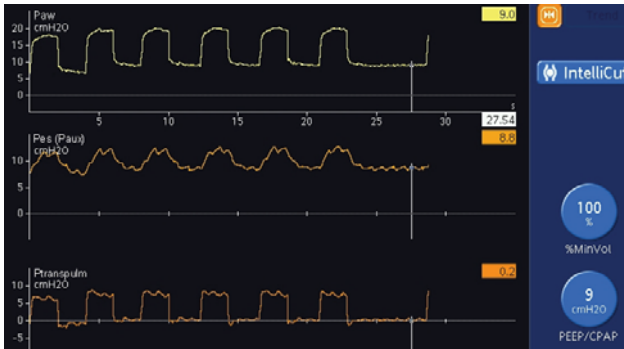
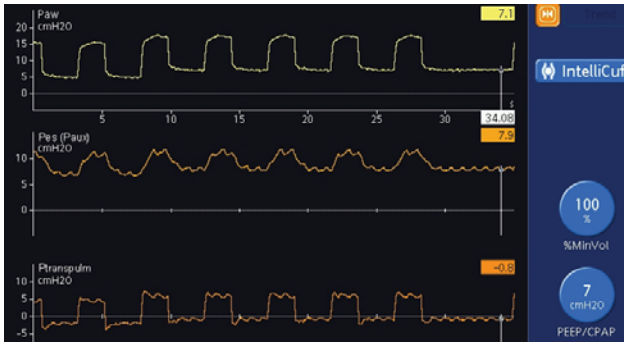


Figure 19: PEEP adjustment according to end-expiratory transpulmonary pressure in an early onset ARDS patient. In each figure, airway, esophageal, and transpulmonary pressures are displayed from top to bottom. The cursor is positioned at the end-expiratory occlusion. In the top figure, PEEP is 7 cmH₂O. Transpulmonary pressure is negative at end-expiration with a high risk of atelectrauma. In the middle figure, PEEP is 9 cmH₂O. Transpulmonary pressure is 0 at end-expiration. In the lower figure, PEEP is 11 cmH₂O. Transpulmonary pressure is around 2 cmH₂O at end-expiration which should prevent atelectrauma

4. Setting tidal volume and inspiratory pressures

Transpulmonary pressure at end-inspiration is measured during an end-inspiratory occlusion and assesses the stress applied to the lung. The recommendation is to set tidal volume or inspiratory pressure in order to keep transpulmonary pressure at end-inspiration below 15 cmH₂O¹² (Figure 20).

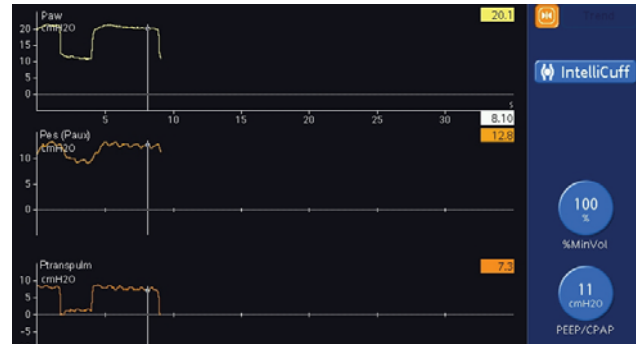


Figure 20: Tidal volume adjustment according to end-inspiratory transpulmonary pressure in an early onset ARDS patient (same patient as in Figure 19). From top to bottom, airway, esophageal, and transpulmonary pressures are displayed. The cursor is positioned at the end-inspiratory occlusion. Transpulmonary pressure is 7 cmH₂O, which is safe in terms of global stress applied to the lung

Other applications

In spontaneously breathing patients, respiratory muscle effort can be assessed by work of breathing or the esophageal pressure-time product. In addition, esophageal pressure measurement is very useful for assessing patient-ventilator synchrony, in particular auto-triggering, inspiratory trigger delay, and ineffective inspiratory efforts.

Limitations

An inappropriate volume to inflate the balloon and an inappropriate position of the catheter in the esophagus will lead to inaccurate measurements. In addition, there is a postural effect due mainly to the weight of mediastinum. It is recommended that esophageal pressure be measured in a semi-recumbent position. Finally, because there is a physiological regional variation in pleural pressure, esophageal pressure estimates the middle pleural pressure.

References

1. Talmor D, Sarge T, O'Donnell C, Ritz R, Malhotra, Lisbon A, Loring S. Esophageal and transpulmonary pressures in acute respiratory failure. *Crit Care Med* 2006; 34:1389–1394
2. Gattinoni L, Chiumello D, Carlesso E, Valenza F. Benchto-bedside review: Chest wall elastance in acute lung injury/acute respiratory distress syndrome patients. *Critical Care* 2004, 8:350-355
3. Hess D, Bigatello L. The chest wall in acute lung injury/acute respiratory distress syndrome. *Curr Opin Crit Care* 2008;14:94–102
4. Akoumianaki E, Maggiore S, Valenza F, Bellani G, Jubran A, et al. The application of esophageal pressure measurement in patients with respiratory failure. *Am J Respir Crit Care Med* 2014;189:520-31
5. Baydur A, Cha EJ, Sassoon CS. Validation of esophageal balloon technique at different lung volumes and postures. *J Appl Physiol* 1987; 62:315–321
6. Loring SH, O'Donnell CR, Behazin N, Malhotra A, Sarge T, Ritz R, et al. Esophageal pressures in acute lung injury: do they represent artifact or useful information about transpulmonary pressure, chest wall mechanics, and lung stress? *J Appl Physiol* 2010;108:515-522
7. Guerin C, Richard JC. Comparison of 2 Correction Methods for Absolute Values of Esophageal Pressure in Subjects With Acute Hypoxemic Respiratory Failure, Mechanically Ventilated in the ICU. *Respir Care* 2012;57:2045–2051
8. Maggiore SM, Jonson B, Richard JC, Jaber S, Lemaire F, Brochard L. Alveolar derecruitment at decremental positive end-expiratory pressure levels in acute lung injury: Comparison with the lower inflection point, oxygenation, and compliance. *Am J Respir Crit Care Med* 2001;164:795–801
9. Demory D, Arnal JM, Wysocki M, Donati SY, Granier I, Corno G, Durand-Gassel J. Recruitability of the lung estimated by the pressure volume curve hysteresis in ARDS patients. *Intensive Care Med* 2008; 34:2019–2025
10. Grasso S, Terragni P, Birocco A, Urbino R, Del Sorbo L, Filippini C, Mascia L, Pesenti A, Zangrillo A, Gattinoni L, Ranieri M. ECMO criteria for influenza A (H1N1)-associated ARDS: role of transpulmonary pressure. *Intensive Care Med* 2012;38:395-403
11. Talmor D, Sarge T, Malhotra A, O'Donnell CR, Ritz R, Lisbon A, Novack V, Loring S. Mechanical ventilation guided by esophageal pressure in acute lung injury. *N Engl J Med* 2008;359:2095-2104
12. Chiumello D, Carlesso E, Cadringer P, Caironi P, Valenza F, Polli F, Tallarini F, Cozzi P, Cressoni M, Colombo A, Marini JJ, Gattinoni L. Lung stress and strain during mechanical ventilation of the Acute Respiratory Distress Syndrome. *Am J Respir Crit Care Med* 2008;178:346-55

Hamilton Medical AG

Via Crusch 8, 7402 Bonaduz, Switzerland

☎ +41 58 610 10 20

info@hamilton-medical.com

www.hamilton-medical.com